

## Short Versus Long Segment Pedicle Screw Fixation Outcome in Thoracolumbar Burst Fracture: A Comparative Analysis

Deepak Beniwal<sup>1</sup>, Rahul Lamba<sup>2</sup>, Prashant Modi<sup>3</sup>, Drvijay Yadav<sup>4</sup>

**Author Affiliation:** <sup>1,2</sup>Resident, <sup>3</sup>Assistant Professor, <sup>4</sup>Senior Resident, Department of Orthopedic, SMS Medical College, Adarsh Nagar, Jaipur, Rajasthan 302004, India.

**Corresponding Author:** Rahul Lamba, Resident, Department of Orthopedic, SMS Medical College, Adarsh Nagar, Jaipur, Rajasthan 302004, India.

**E-mail:** rahul.lamba5868@gmail.com

**Received:** 24.07.2019 **Accepted on:** 09.12.2019

### How to cite this article:

Deepak Beniwal, Rahul Lamba, Prashant Modi, et al. Short Versus Long Segment Pedicle Screw Fixation Outcome in Thoracolumbar Burst Fracture: A Comparative Analysis. J Orthop Educ. 2019;5(3):131–140.

### Abstract

*Introduction:* Thoracolumbar burst fractures, frequently associated with kyphotic deformity and neurological deficit are very common in younger patients and could have a great impact on their daily physical activities. The primary goal of treatment of the thoracolumbar fracture is keeping patients alive, protecting from the further neural damage, obtaining the stability by reconstructing anatomical alignment of spinal columns and returning patients to workplace through early mobilization and rehabilitation. *Aim:* Comparison between two groups which includes short segment fixation (fracture vertebrae and long segment fixation with pedicle screw). *Material and Methods:* This Hospital based Prospective Randomized comparative interventional study between two groups in Department of Orthopaedics SMS Medical College and hospital Jaipur from Nov 2016 to Oct 2018. It included 25 cases of acute, traumatic fractures of the thoracolumbar junction (T9-L3) treated with short segment pedicle fixation one level above and one level below the fractured vertebra including at least one pedicle screw in fractured vertebrae and 25 cases are treated with long segment pedicle screw fixation included the instrumentation at least of two vertebrae above and two vertebrae below the fracture. Complete clinical and neurological examination was done. *Observations and Results:* The surgical management of thoracolumbar burst fractures through posterior approach, the short segment pedicle screws fixation was not significantly different to the long segment pedicle screws fixation in terms of correction of kyphotic deformity improvement of back pain and return to work and also in LS instrumentation prolonged the operative time and increased the amount of blood loss significantly. SFIFL offers significant advantages such as incorporating fewer motion segments in the fusion, shorter operative time and maintenance of the correct sagittal alignment. Partial neurologic deficits have potential for recovery, the amount depending more on the initial deficit and the time elapsed since the initial deficit than the treatment strategy. Serious complications are rare. *Conclusion:* Short-segment instrumentation using additional screws at the fracture level in thoracolumbar burst fractures is a proper surgical approach for obtaining clinically and radiologically successful results in terms of the kyphosis angle in a maintenance of the sagittal alignment this technique allowed to save two or more segments of vertebral motion, operative time and blood loss as compared to long segment fixation.

**Keywords:** Thoracolumbar burst fractures; Kyphosis angle, Short segment pedicle screw fixation.

## Introduction

Spine trauma is devastating injuries which might result in serious disabilities and direct consequences especially if managed inappropriately.<sup>1</sup>

Thoraco-lumbar injuries constitute the major proportion of trauma involving the spine. Most spinal fractures occur between T11 & L4 and around 14% to 17% are classified as the burst type.

The susceptibility of this region is due to the loss of stabilization caused by the ribs and chest muscles, the transition between kyphotic thoracic and lordotic lumbar curvature, and the change in facet joint orientation, from coronal in the thoracic spine, to sagittal in the lumbar spine.<sup>2</sup>

Thoracolumbar burst fractures, frequently associated with kyphotic deformity and neurological deficit are very common in younger patients and could have a great impact on their daily physical activities.<sup>3</sup>

The primary goal of treatment of the thoracolumbar fracture is keeping patients alive, protecting from the further neural damage, obtaining the stability by reconstructing anatomical alignment of spinal columns and returning patients to workplace through early mobilization and rehabilitation.<sup>4</sup>

The indicators for treatment of burst fractures are also the mechanical and neurological stability of fractures. The conservative treatment using orthosis is mostly recommended for stable burst fractures but the operative treatment is required for unstable burst fractures.<sup>5</sup>

The operative treatment for burst fractures is generally performed when there is neurological or mechanical instability and its goal is decompression of spinal canal and nerve root for neurological recovery, restoration and maintenance of vertebral height and spinal alignment, rigid fixation for early ambulation and rehabilitation, and prevention of progressive neurological injury and kyphotic deformity. The pedicle screw fixation is the most commonly used for the fixation of fractures with the posterior approach. This pedicle screw has an advantage of being able to fix three columns of spine. Due to the development of instruments, strength of the screws is improved and the use of short segment fixation, which fixes the above and below segment of fracture site, has been increasing. However, there were studies that the failure rate of this short segment fixation was 20% to 50% and the loss of reduction was 50% to 90%.<sup>6</sup>

McCormack et al.<sup>14</sup> suggested load sharing classification (LSC) in order to predict the prognosis of short segment fixation using posterior approach. This classification divided spine fractures into 3 categories according to the amount of damaged vertebral body, the spread of the fragments in the fracture site and the amount of corrected traumatic kyphosis; then, each category was scored from 1 to 3 according to the degree. When the total score is more than 6 points, they insisted that the long segment fixation, which fixes at least more than two segments of above and below the fracture site.<sup>14</sup> This prospective study is to compare the outcomes of traditional long segment fixation (two levels above and two levels below excluding the fracture level) and the short segment fixation including fracture level (one level above and one level below including the fracture level) in unstable thoracolumbar fracture cases.

## Materials and Methods

This Hospital based Prospective Randomized comparative interventional study between two groups in Department of Orthopaedics SMS Medical College and hospital Jaipur from Nov 2016 to Oct 2018. It included 25 cases of acute, traumatic fractures of the thoracolumbar junction (T9-L3) treated with short segment pedicle fixation one level above and one level below the fractured vertebra including at least one pedicle screw in fractured vertebrae and 25 cases are treated with long segment pedicle screw fixation included the instrumentation at least of two vertebrae above and two vertebrae below the fracture. Complete clinical and neurological examination was done. The level of spine injury was assessed clinically and radio logically. The patients were divided into two groups according to the number of instrumented levels.

*Group 1:* included 25 patients treated by short-segment fixation with inclusion of the fracture level (SSFIFL). The SSFIFL were performed using two screws one level above and below the fracture and at least one pedicle screw at the fracture level.

*Group 2:* included 25 patients treated by long-segment fixation (LSF) with eight screws: two levels above and below the fracture. Patients of age Group 18-55 year with unstable acute thoracolumbar fracture include more than 50% loss of vertebral body height, local kyphosis of more than 15°, burst-type fracture with more than 25%, retropulsion into the canal, Patient with a single-level burst fracture

between T11-L3, integrity of at least one pedicle in the fractured vertebra, less than 3 weeks from the time of injury, fit for surgery and anesthesia. While patients with pathological thoracolumbar burst fractures, associated with any other level of spine fracture, associated major long bone fracture were excluded.

A seriously injured patient should initially be assumed to have an unstable spinal injury. Movement at the level of an unstable fracture can cause further neurological deficit, and so patients suspected of having a spinal injury should be handled with the minimum amount of force and movement applied to the spine. At the scene of injury, the patient is immobilized with a spinal board, a rigid cervical collar, neck blocks and straps.<sup>7</sup>

**Primary survey were one done**

*Disability – the neurological examination*

A rapid assessment of central neurological function is made using the Glasgow Coma Scale. If a spinal injury or neurological deficit is identified, a detailed peripheral neurological examination is required. The American Spinal Injuries Association (ASIA) chart guides examination and allows an accurate and reproducible record to be made. Neurological assessment in the conscious patient includes

- Sensory function in all dermatomes (light touch and pin prick) on each side of the body innervated by C5 to T1 and L2 to S1 with pin prick assessment at 28 specific sensory dermatomes on each side of the body
- Muscle power This includes testing motor power of ten muscles using the MRC grading scale reflexes in the upper and lower limbs
- Rectal examination, including perianal and perineal sensation bilaterally, and anal tone and anal sphincter contraction.

The ASIA recommends the following ten key muscle groups and their corresponding nerve root levels are tested in a patient with spinal cord injury.

Level	Muscle group
C5	Elbow flexors – Brachialis and Biceps
C6	Wrist extensors – Extensor carpi radialis longus and Brevis
C7	Elbow extensors – Triceps
C8	Finger flexors – Flexor digitorum profundus to middle Finger
T1	Small finger abductors – Abductor digit minimi
L2	Hip flexors – Iliopsoas
L3	Knee extensors – Quadriceps
L4	Ankle dorsiflexors – Tibialis anterior

Level	Muscle group
L5	Long toe extensors – Extensor hallucis longus
S1	Ankle plantar flexors – Gastrocnemius and Solleus

The functional consequences of spinal cord injury are described by the severity of neurological dysfunction as complete and incomplete injuries.<sup>5,4</sup>

Spinal injury patients are assessed by radiological methods following clinical evaluation. Systematic radiological evaluation is necessary to avoid missed injuries.

**Lateral thoracic/lumbar spine**

White and Panjabi defined instability as the loss of ability of the spine to maintain relationships between vertebrae under physiological loads. The checklist for the diagnosis of clinical instability includes the following in which a score of 5 or more indicates instability.

**White and Panjabi Thoraco lumbar Instability Scale**

S. No.	Element	Points
1	Anterior element unable to function	2
2	Posterior element unable to function	2
3	Disruption of Costovertebral articulations	1
4	Sagittal plane displacement (T) > 2.5 mm; (L) > 4.5 Mm	2
5	Sagittal plane angulation (T) > 5 deg; (L) > 22 deg	2
6	Spinal cord or Cauda equine damage	2
7	Dangerous load anticipated	1

**Instability: Total Points ≥ 5**

In general CT scan is indicated for patients with suspected spinal fractures and dislocation that are not identified on plain radiographs and patients with incomplete visualization of the spinal column. Excellent bony detail of the fracture pattern usually can be obtained with CT scan.

The MRI is indicated in every spinal cord injured patients to assess the status of the cord, disc and posterior ligamentous complex. It also detects the spinal cord edema and haematoma. It is 90% sensitive and 100% specific.

**Management**

Vaccaro AR in 2005 proposed Thoracolumbar Injury Severity Score helps to determine whether operative treatment of the thoracolumbar spinal injuries is appropriate for that particular fracture pattern.<sup>8</sup>

In the presence of a progressive neurological deficit, emergency decompression is indicated. Implant options in the management of Thoracolumbar fractures include the following Posterior Instrumentation:<sup>9</sup> Non-segmental - Rod and hook system (Harrington rod), Hybrid system- (Luque rod, Harrington rod with sublaminar wires), Segmental system Rod and hook constructs, Extended pedicle screw constructs, Short-segment pedicle instrumentation and Compression instrumentation.

The pedicle screw system includes the monoaxial and polyaxial system and depending on the locking screws available. They are single locking screws and double locking screws.

**Operative Techniques**

General anesthesia was given by a cuffed endotracheal tube. The level of the injured spine as marked by C arm was taken as centre of the incision. The dorsolumbar spine was approached by midline incision and the dorsolumbar fascia was incised in line with skin incision. The spinous processes were identified and the plane between spinous processes and paraspinal muscles laterally was made. The paraspinal muscles were erased sub periosteally and reflected laterally with a self retaining spinal retractor. The pedicles were identified by a point where the middle of the transverse process and the longitudinal axis of the superior facet meet. The pedicle screws were passed under image intensifier control after probing the pedicle and measuring its depth. The commonly used screw size in our study includes 5.5 mm for thoracic pedicles and 6.5 mm for lumbar pedicles. Then the pedicle screws were bridged with two connecting rods fixed with an inner screw. Decompressive laminectomy was done after fixing the screws to decompress the neural elements if needed. In 4 patients with burst fractures we found the retropulsed fragments compressing the thecal sac were pushed anteriorly into body.

Reduction of the fracture and indirect decompression of the spinal cord were accomplished by means of the rod contouring and the compression distraction forces applied before tightening the screws.

All operations were performed by the senior surgeons, using the same instrumentation system, with screws size chosen according to the vertebra size (6.5 × 45 mm screws and 5 mm rods most of the time). Reduction of the fracture and indirect decompression of the spinal cord were accomplished by means of the rod contouring and

the compression distraction forces applied before tightening the screws.

Laminectomy was performed according to the presence of compression on neural tissue in preoperative imaging. Wound closed in layers with a negative suction drain after attaining perfect haemostasis.

All the patients were turned sideways periodically in the 24 hrs post operative period. Drainage tube was removed at 48 hours. They were allowed to sit after wearing a Taylor’s brace with a back support on 15<sup>th</sup> postoperative day. Suture removal was done on 15<sup>th</sup> day. Active assisted and passive exercises were taught to keep the joints supple. Clean intermittent self catheterization was taught in the post operative period.

All the patients were advised to continue the Taylor’s brace for the first 3 months after the surgery. They were followed up every month till 6 months and then every 2 months during the next 6 months. The minimum follow up in our study is 6 months and the maximum follow up is one year. During the follow up period the pain and working ability were assessed using Denis pain and work assessment scale and also evaluated clinically and radiologically

Direct and/or indirect signs of implant failure (such as screw breakage, rod displacement/ breakage and screw head dislodgement) were checked at follow-up imaging. Neurologic assessment was tested using the American Spinal injury Association (ASIA) grading system

**Denis Pain Scale**

P1	No pain
P2	Occasional minimal pain; no need for medication
P3	Moderate pain, occasionally medications in interruption of work or activities of daily living
P4	Moderate to severe pain, occasionally absent from work; significant changes in activities of daily living
P5	Constant, severe pain; chronic pain medications

**Denis Work Scale**

W1	Return to previous employment (heavy labor) or physically demanding activities
W2	Able to return to previous employment (sedentary) or return to heavy labor with restrictions
W3	Unable to return to previous employment but works full time at new job
W4	Unable to return to full time work
W5	No work, completely disabled

**Results**

This study was conducted in Department of Orthopaedics at the S.M.S. Medical College Jaipur, Rajasthan from Nov 2016 to Oct 2018. A total of 58 patients enrolled in the study, 8 pts were lost in follow up due to non-compliance.

The age range of the patients in Group 1 was 21-50 yrs. The age range in Group 2 was also 21 to (average age: 40.4) years. Minimum age in Group 1 was.  $p = 0.803$  NS. The mean age was  $33.80 \pm 6.90$  for group1 (SSFIFL) and  $33.88 \pm 7.61$  for Group 2 (LSF) respectively with no significant difference ( $p = 0.942$ ). Our study comprised of total 76% male and 24% female in both groups. The female: male ratio was 1:3. Two groups were similar with regard to age and sex. The two most common mode of injury in our study was due to RTA (54%) and fall from height (44%) Chi-square = 0.584 with 4 degrees of freedom;  $p = 0.965$ . Thoracolumbar fractures between T11 and L3 were included in this study. L1 fracture was sustained by 32% of the patients in

the first group and 28% in the second group. When Groups 1 and 2 were compared according to the fracture level, the results were as follows: T11:4/4, T12:5/5, and L2:6/4. ( $p = 0.453$ )  $p = 0.719$ . In Group 1 (SSFIFL), based on the ASIA scale, at admission 18 patients (72%) had no neurological deficit (ASIA E); one patient (4%) had ASIA C, three patients (12%) had ASIA B, three patient (12%) had complete injury (ASIA A) Follow-up neurological status was assessed as following: ASIA E (22 patients: 88%), ASIA B (1 patients: 4%), ASIA A (2 patient: 8%). In conclusion, four patients out of 7 (57.14%) showed neurological improvement. In Group 2 (LSF), at admission, 19 patients (76%) had ASIA E; three patients ASIA C (12%); one patient ASIA B(4%); two patients (8%) ASIA A, and one patient (3.33%) ASIA A. At follow-up in Group 2, 22 patients (88%) had no neurological deficit (ASIA E), one patient (4%) ASIA C and another patient (8%) ASIA A. In this group, three patients out of six (50%) recovered at least one ASIA grade. Statistical analysis showed no difference between the two groups ( $p > 0.05$ ). (Table 1).

**Table 1:** Characteristics of the study population

		Group 1 (N = 25)		Group 2 (N = 25)		Grand total		p value LS
		No	%	No	%	No	%	
Age groups	21-30	9	36	8	32	17	34	
	31-40	11	44	10	40	21	42	
	41-50	5	20	7	28	12	24	
	Age	$33.8 \pm 6.9$		$33.96 \pm 8.41$		$33.88 \pm 7.61$		
Gender	Female	7	28	5	20	12	24	0.74 NS
	Male	18	72	20	80	38	76	
Mode of injury	FFH	11	44	12	48	22	44	1.0 NS
	RTA	14	56	13	52	27	54	
Fracture level	D11	4	16	4	16	8	16	0.96 NS
	D12	5	20	5	20	10	20	
	L1	8	32	7	28	15	30	
	L2	6	24	4	16	10	20	
	L3	2	8	3	12	5	10	
Magerl classification	A2	10	40	13	52	23	46	0.45 NS
	A3	12	48	12	48	24	48	
	B2	2	8	0	0	2	4	
	B3	1	4	0	0	1	2	

Mean operative time was significantly shorter in the Group 1 of SSFIFL ( $148.5 \pm 21.54$  min) than in Group 2 of LSF ( $172 \pm 22.19$  min;  $sp < 0.05$ ). There were no implant failures, including screw breakages or loosening in both groups. The average preoperative LKA was  $21.32^\circ \pm 4.70^\circ$  in Group 1 (SSFIFL), while in Group 2 (LSF) was  $22.72^\circ \pm 5.72$  ( $p = 0.346$ ). Postoperative correction was slightly better in Group 2 than in Group 1. In

fact, the mean postoperat  $16.80^\circ \pm 5.29^\circ$  for Group 2 (LSF) with an average correction of  $6.87$  and  $5.9^\circ$  respectively is there. However, this difference was not statistically significant ( $p = 0.243$ ). Moreover, there was no significant difference of correction loss between the two Groups at the last follow-up. In fact, the mean LKA at last follow-up was  $15.72 \pm 5.94^\circ$  for Group 1 of SSFIFL and  $18.37 \pm 5.30^\circ$  for Group 2 of (LSF). Correction loss in Group 2 ( $1.5^\circ$ )

was slightly less than in Group 1 (1.74°) without no statistical relevance ( $p = 0.104$ ). These results are summarized in Table 2. To conclude, the two

groups were similar both in terms of postoperative sagittal alignment restoration and correction loss at last follow-up.

**Table 2:** Comparative analysis of pre and post ASIS scale among the groups

		Group 1 (N = 25)		Group 2 (N = 25)		Grand total		p value LS
		No	%	No	%	No	%	
ASIS scale preop	A	3	12	2	8	5	10	0.36 NS
	B	3	12	1	4	4	8	
	C	1	4	3	12	4	8	
	E	18	72	19	76	37	74	
ASIS scale postop	A	2	8	2	8	4	8	0.229 NS
	B	1	4	0	0	1	2	
	C	0	0	1	4	1	2	
	E	22	88	22	88	44	88	

**Anterior body height (ABH) of the fractured vertebra**

The anterior vertebral height was  $16.82 \pm 4.62$  mm preoperatively,  $19.47 \pm 4.17$  mm postoperatively, and  $19.02 \pm 4.03$  mm at the follow-up in Group 1 (SSFIFL) and it was  $15.70 \pm 4.16$  mm preoperatively,  $18.03 \pm 4.28$  mm postoperatively, and  $17.66 \pm 4.25$  at the follow-up in Group 2 (LSF). These results were not statistically significant for either of the groups

**Posterior body height (PBH) of the fractured vertebra**

The posterior vertebral height was  $24.5 \pm 4.23$  mm preoperatively,  $25.99 \pm 3.81$  mm postoperatively, and  $25.75 \pm 3.78$  mm at the follow-up in Group 1 (SSFIFL) and it was  $24.64 \pm 3.67$  mm preoperatively,  $25.20 \pm 3.70$  mm postoperatively, and  $24.44 \pm 3.61$  at the follow-up in Group 2 (LSF). These results were not statistically significant for either of the groups

**ABH/PBH ratio of the fractured vertebra**

The average ABH/PBH ratio was  $0.67 \pm 0.10$  preoperatively,  $0.75 \pm 0.10$  postoperatively, and  $0.73 \pm 0.09$  at last follow-up in Group1 (SSFIFL), while it was  $0.63 \pm 0.09$  preoperatively,  $0.73 \pm 0.09$  postoperatively, and  $0.71 \pm 0.08$  at last follow-up in Group 2 (LSF) (Table 3). The results show the absence of statistical significant differences between Groups 1 and 2 in terms of restoration of fractured vertebral body shape ( $p = 0.515$ ) and maintenance of the restoration over the time ( $p = 0.470$ ). Changes of the ABH/PBH ratio, which reflect the fracture induced wedge shape of the vertebral body, are presented in Table 3. Surgery resulted in an almost complete reconstruction of the original shape of the vertebral body in both groups. At the time of follow-up, we recorded insignificant reduction of the ABH/PBH ratio in Group 1 and Group 2. (Table 3).

**Table 3:** Comparative analysis of outcome variables among the groups

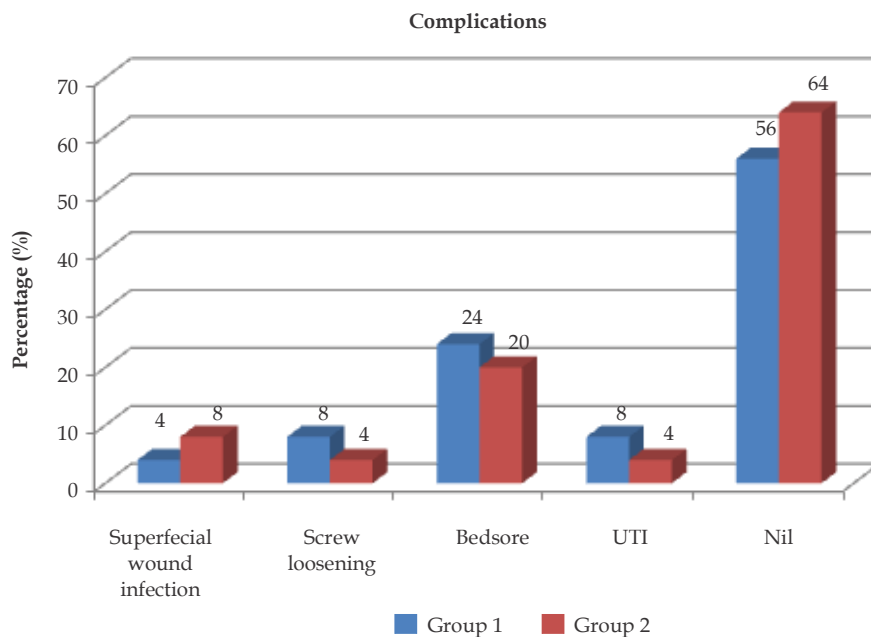
Group	Group	Group 1		Group 2		Total		p value LS
		Mean	SD	Mean	SD	Mean	SD	
LKA	operative time	91.8	7.76	105.6	22.93	98.7	18.32	0.006
	preop	21.32	4.7	22.72	5.72	22.02	5.23	0.346
	postop	14.45	6.12	16.8	5.29	15.6	5.3	0.15
	follow up	15.72	5.94	18.37	5.33	17.04	5.74	0.104
ABH	preop	16.82	4.62	15.7	4.16	16.26	4.39	0.374
	postop	19.47	4.17	18.03	4.28	18.75	4.24	0.233
	follow up	19.02	4.03	17.66	4.25	18.34	4.16	0.25
PBH	preop	24.56	4.23	24.64	3.67	24.6	3.92	0.943
	postop	25.99	3.81	25.2	3.7	25.59	3.73	0.461
	follow up	25.75	3.78	24.44	3.61	25.09	3.72	0.214
ABH/PBH	preop	0.67	0.1	0.63	0.09	0.65	0.1	0.113
	postop	0.75	0.1	0.73	0.09	0.74	0.09	0.515
	follow up	0.73	0.09	0.71	0.08	0.72	0.09	0.47

**Table 4:** Distribution of the cases according to denis pain scale

	Group 1 (N = 25)		Group 2 (N = 25)		Grand total		p value LS
	No	%	No	%	No	%	
<b>Denis Pain scale</b>							
P1	9	36	10	40	19	38	0.83 NS
P2	9	36	7	28	16	32	
P3	7	28	8	32	15	30	
<b>Danis Work Scale</b>							
W2	14	56	14	56	28	56	0.87 NS
W3	8	32	9	36	17	34	
W4	3	12	2	8	5	10	

In our study Denis pain scale showed that 36% of patients had minimal pain, 36% of patient had moderate pain and 28% had moderate to severe pain in Group 1. While in Group 2 40% of patient had minimal pain, 28% had moderate to severe pain and 32% had severe pain the Denis work assessment scale showed that 33.33% of patients had unable to return to the previous job but can able to work full time with job modification, 26.67% of patients cannot able to work full time and 40% of patients were completely disabled. (Table 4).

Complications included one case wound infection, two cases of screw loosening, six cases bed sore and two cases of UTI in Group 1 and two case wound infection, one cases of screw loosening, five cases bed sore and one cases of UTI in Group 2. Bed sore were managed by antibiotics, dressings and periodical turning o patients, Urinary tract infection managed by appropriate parenteral antibiotics and bladder wash with Povidone iodine and normal saline. Postoperative superficial wound infection which was settled with regular dressings and antibiotics. (Fig. 1)



**Fig. 1:** Complications among the groups

**Discussion**

All cases in our study underwent surgery was performed between minimum period of 3 days to maximum 3 weeks of injury. Two most common modes of injury were fall from height and road

traffic accidents.

The groups were similar with regard to age, sex, trauma etiology, fracture level, fracture type (according to the Magerl classification), neurologic status (according to the ASIA impairment scale), and follow-up.

The mean age was  $33.80 \pm 6.90$  for Group 1 (SSFIFL) and  $33.88 \pm 7.61$  for Group 2 (LSF) respectively with no significant difference ( $p = 0.942$ ). Our study comprised of total 76% male and 24% female in both groups. This is accordance to the known literature that thoracolumbar fracture is more common in males than females. The two most common mode of injury in our study was due to RTA (54%) and fall from height (44) Thoracolumbar fractures between T11 and L3 were included in this study. L1 fracture was sustained by 32% of the patients in the first group and 28% in the second group. When Groups 1 and 2 were compared according to the fracture level, the results were as follows: T11 16% in both groups, T12 20% in both groups, L2 24% in Group 1 and 16% in Group 2, L3 8% in Group 1 and 12% in Group 2.

According to magrel classification (1994) Type A fractures represented 90% of all injuries. Type B and C lesions, although they encompass a great variety of injuries, altogether only accounted for 8% in our study.

In our series, 8% patients had complete deficit (ASIA A) and 92% had incomplete neurological deficit (2%-ASIA B, 2%-ASIA C, and 88%-ASIA E) resulting from the trauma. Farrokhi MR (2010)<sup>10</sup> and Kanna RM et al. [2015]<sup>11</sup> reported that 22.7% and 85% patients with neurological deficit, respectively, had a complete impairment (ASIA A). The neurological outcome in our study was similar in both group four patients out of 7 (57%) improved in Group 1 and three patients out of six (50%) improved in Group 2 of at least one ASIA grade. Following the literature, a complete paraplegia did not resolve and the few patients that did improve more than one scale (including two patients with complete paraplegia that recovered completely) might have been diagnosed too pessimistically at admission or might have had other than pure disruptive mechanical causes of paraplegia<sup>12</sup> Patients with the least deficits at admission clearly had the best prospects of complete recovery regardless of the surgical group they were into. At least two mechanisms could be involved in this finding.

The posterior approach is used in all cases in our study. This approach is used more frequently among spinal surgeons because of its easy application, reduction of bleeding, and small incision area<sup>13</sup>

Denis pain and work scale was used to assess the improvement of back pain in posterior short segment fixation or posterior long segment fixation treated patients during the follow-up periods which are of 6 months. Pain relief and radiological

correction are major outcome criteria for surgical treatment of thoracolumbar burst fractures from the patient's perspective.

In our study, mean operative time was significantly shorter in the Group 1 of SSFIFL ( $148.5 \pm 21.54$  min) than in Group 2 of LSF ( $172 \pm 22.19$  min;  $<0.05$ ). Long segment instrumentation prolonged the operative time and increased the amount of blood loss significantly. Similar results are found by Tezeren and Kuru (2005)<sup>14</sup> and Tarek Ahmed Aly (2017)<sup>15</sup> in their study comparing short segment versus long segment fixation in thoracolumbar burst fractures.<sup>8</sup>

Homogeneity was observed also in terms of local kyphosis angle (LKA), anterior body height (ABH), posterior body height (PBH), and ABH/PBH ratio at preoperative evaluation. The average preoperative LKA was  $21.32^\circ \pm 4.70^\circ$  in Group 1 (SSFIFL), while in Group 2 (LSF) was  $22.72^\circ \pm 5.72^\circ$  ( $p = 0.346$ ).

Reduction of post-traumatic kyphosis (assessed with LKA) and restoration of fracture-induced wedge shape of the vertebral body (ABH/PBH ratio, ABH and PBH) at immediate postoperative period were not significantly different between Group 1 of SSFIFL and Group 2 of LSF. However, this difference was not statistically significant ( $p = 0.243$ ). There was also no significant difference between the two groups in terms of loss correction at the last follow-up.

The present study confirms that intra-operative fracture reduction and correction of sagittal deformity can be easily achieved via the placement of screws at the fracture level, according to the hypothesis of Guven et al. (2009)<sup>16</sup> and Ökten Aİ, et al. (2015)<sup>17</sup> found in their studies that the use of screws placed within the fractured vertebra can enhance the stability of construct and prevent loss correction over the time.<sup>18</sup> Dobran et al.<sup>19</sup> also have shown that including the fracture level in short-segment fixation to treat thoracolumbar junction fractures results in kyphosis correction and maintenance similar to that in the case of long-segment fixation, with similar neurological outcomes

In many studies, the correction of the kyphosis angle observed in the early postoperative period decreased in long-term controls.<sup>20</sup> In our experience, a short instrumentation with inclusion of fracture level ensures the same loss correction of long construct.

In this series, SSFIFL offers significant advantages such as incorporating fewer motion segments in the



fusion, shorter operative time, and maintenance of the correct sagittal alignment.

Despite increasing experience, knowledge and technical advancement, pedicle screw insertion is still associated with a certain degree of complications. A review of the literature showed that Short-segment posterior fixation alone led to a 9%–54% incidence of implant failure and re-kyphosis in the long-term follow-up, and 50% of the patients with implant failure had moderate-to-severe pain.<sup>21</sup> In our study most common complications was bed sore followed by screw loosening.

Lonstein JE in 1999 reported the most common complication is screw malpositioning, with an overall incidence of 0–42%. Most of them are asymptomatic without any major sequelae, and serious screw-related complications, such as neurological, visceral, or vascular are very rare.<sup>22</sup>

On the basis of our study we finally concluded that Short-segment instrumentation using additional screws at the fracture level in thoracolumbar burst fractures is a proper surgical approach for obtaining clinically and radiologically successful results in terms of the kyphosis angle in a maintenance of the sagittal alignment this technique allowed to save two or more segments of vertebral motion, operative time and blood loss as compared to long segment fixation.

## References

1. Michael W. Chapman. *Chapman's Orthopaedic Surgery*, 3<sup>rd</sup> Edition. Lippincott Williams and Wilkins. 2000.pp.3713–14.
2. Knight RQ, Stornelli DP, Chan DP, et al. Comparison of operative versus nonoperative treatment of lumbar burst fractures. *Clin Orthop Relat Res*. 1993;293:112–21.
3. Byung-Guk Kim, Jin-Myoung Dan, Dong-Eun Shin. Treatment of Toracolumbar Fracture. *Asian Spine J*. 2015 Feb;9(1):133–146.
4. Tarek Ahmed Aly. Short Segment versus Long Segment Pedicle Screws Fixation in Management of Toracolumbar Burst Fractures: Meta-Analysis. *Asian Spine J*. 2017 Feb;11(1):150–160.
5. Vaccaro AR, Lim MR, Hurlbert RJ, et al. Surgical decision making for unstable thoracolumbar spine injuries: results of a consensus panel review by the Spine Trauma Study Group. *J Spinal Disord Tech*. 2006 Feb;19(1):1–10.
6. McLain RF, Sparling E, Benson DR. Early failure of short-segment pedicle instrumentation for thoracolumbar fractures: A preliminary report. *J Bone Joint Surg Am*. 1993 Feb;75(2):162–7.
7. Gomleksiz C, Egemen E, Senturk S, et al. Thoracolumbar Fractures: A Review of Classifications and Surgical Methods. *J Spine* 2015;4:250. doi:10.4172/2165-7939.100025.
8. Vaccaro AR, Zeiller SC, Hulbert RJ, et al: The thoracolumbar injury severity score: A proposed treatment algorithm. *J Spinal Disord Tech*. 2005 Jun;18(3):209–15.
9. John W. Frymoyer, Sam W. Wiesel et al. *Adult & Pediatric Spine*, Lippincott Williams and Wilkins 3<sup>rd</sup> Edition 2003.p.834.
10. Farrokhi MR, Razmkon A, Maghami Z, et al. Inclusion of the fracture level in short segment fixation of thoracolumbar fractures. *Eur Spine J*. 2010;19(10):1651–6.
11. Kanna RM, Shetty AP, Rajasekaran S. Posterior fixation including the fractured vertebra for severe unstable thoracolumbar fractures. *Spine J*. 2015;15(2):256–64.
12. Waters RL, Adkins RH, Yakura JS, et al. Motor and sensory recovery following incomplete paraplegia. *Arch Phys Med Rehabil*. 1994 Jan;75(1):67–72.
13. Hu R, Mustard CA, Burns C. Epidemiology of incident spinal fracture in a complete population. *Spine (Phila Pa 1976)*. 1996 Feb 15;21(4):492–9.
14. Tezeren G, KuruI. Posterior fixation of thoracolumbar burst fracture: short-segment pedicle fixation versus long-segment instrumentation. *J Spinal Disord Tech*. 2005;18(6):485–8.
15. Tarek Ahmed Aly. Short Segment versus Long Segment Pedicle Screws Fixation in Management of Toracolumbar Burst Fractures: Meta-Analysis *Asian Spine J*. 2017;11(1):150–60.
16. Guven O, Kocaoglu B, Bezer M, et al. The use of screw at the fracture level in the treatment of thoracolumbar burst fractures. *J Spinal Disord Tech*. 2009;22:417–21.
17. Ökten Aİ, Gezercan Y, Özsoy KM, et al. Results of treatment of unstable thoracolumbar burst fractures using pedicle instrumentation with and without fracture-level screws. *Acta Neurochir (Wien)*. 2015;157(5):831–6.
18. Kanna RM, Shetty AP, Rajasekaran S. Posterior fixation including the fractured vertebra for severe unstable thoracolumbar fractures. *Spine J*. 2015;15(2):256–64.
19. Dobran M, Nasi D, Brunozzi D. Treatment of unstable thoracolumbar junction fractures: short-segment pedicle fixation with inclusion of the fracture level versus long-segment instrumentation. *Acta Neurochir (Wien)*. 2016 Oct;158(10):1883–9.

20. Pandey V, Nigam V, Goyal TD, et al. An evaluation of the factors affecting neurological recovery following spinal cord injury. *Injury*. 1997 Oct;28(8):545-8.
21. Waters RL, Adkins RH, Yakura JS. Motor and sensory recovery following incomplete paraplegia. *Arch Phys Med Rehabil*. 1994 Jan;75(1):67-72.
22. Burns AS, Ditunno JF. Establishing prognosis and maximizing functional outcomes after spinal cord injury: a review of current and future directions in rehabilitation management. *Spine (Phila Pa 1976)*. 2001 Dec 15;26(24 Suppl):S137-45

